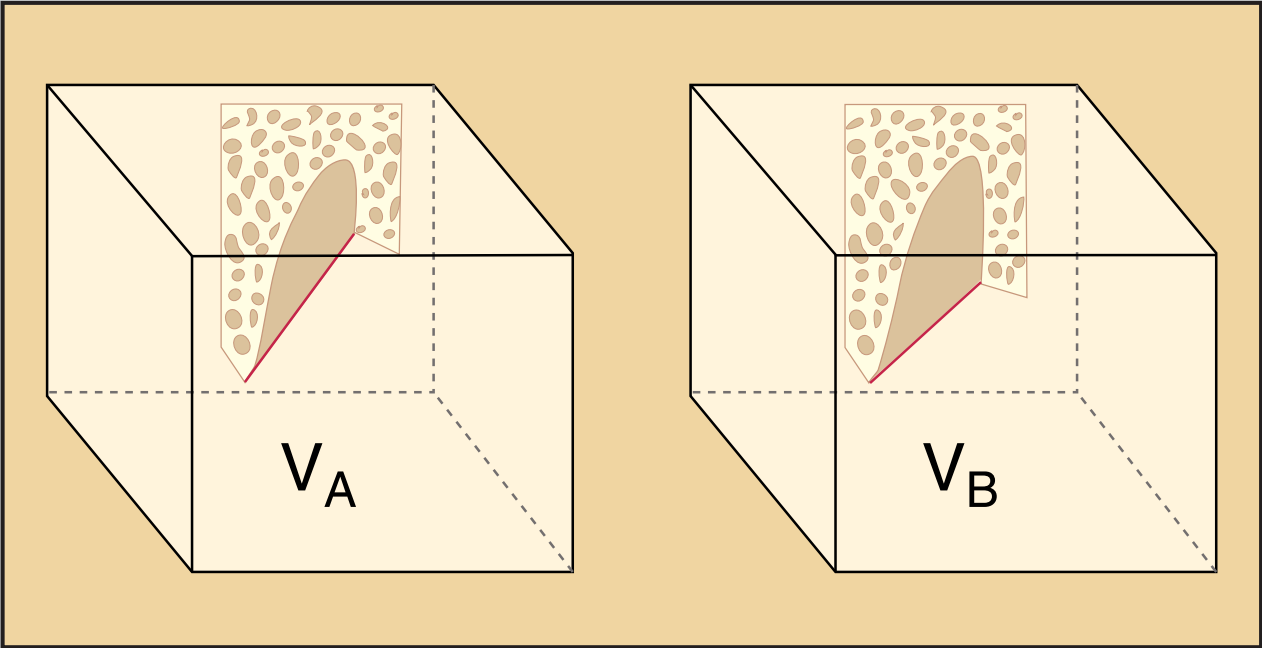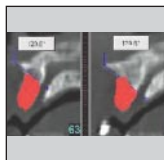


Measuring the Efficacy of rhBMP-2 to Regenerate Bone: A Radiographic Study Using a Commercially Available Software Program



Jorge Bianchi, MMSc*/Joseph P. Fiorellini, DMD, DMSc**/
T. Howard Howell, DDS***/Julio Sekler, Dr Odont, MMSc, DMD****/
Hugh Curtin, MD*****/Marc L. Nevins, DDS, MMSc*****/
Bernard Friedland, BChD, MSc, JD*****

This radiographic study evaluated the efficacy of different concentrations of rhBMP-2 to regenerate bone in alveolar defects in the anterior maxilla. The study was performed using reasonably standardized CT examinations and the Simplant program. The radiographic measurements were further refined by careful standardization of the measured regions of interest. There was a statistically significant difference in bone formation between subjects treated with a concentration of 1.5 mg/mL rhBMP-2 compared with each of the other groups. There was no statistically significant difference in bone volume between any of the other groups. None of the groups showed a loss in bone volume. (Int J Periodontics Restorative Dent 2004;24:579–587.)

*Formerly, Research Fellow, Department of Oral Medicine, Infection and Immunity, Harvard School of Dental Medicine, Boston; Currently, Private Practice, Oral and Maxillofacial Radiology, Santiago, Chile.

**Associate Professor, Department of Oral Medicine, Infection and Immunity, Harvard School of Dental Medicine, Boston.

***Professor, Department of Oral Medicine, Infection and Immunity, Harvard School of Dental Medicine, Boston.

****Research Fellow, Department of Oral Medicine, Infection and Immunity, Harvard School of Dental Medicine, Boston.

*****Professor, Department of Radiology, Harvard Medical School/ Massachusetts Eye and Ear Infirmary, Boston.

*****Clinical Instructor, Department of Oral Medicine, Infection and Immunity, Harvard School of Dental Medicine, Boston.

*****Assistant Professor, Department of Oral Medicine, Infection and Immunity, Harvard School of Dental Medicine, Boston.

Correspondence to: Dr Bernard Friedland, Harvard School of Dental Medicine, Department of Oral Medicine, Infection and Immunity, 188 Longwood Avenue, Boston, Massachusetts 02115. e-mail: bernard_friedland@hsdm.harvard.edu

Adequate bone volume is a requirement for successful placement of dental implants and their long-term retention.¹ Where bone is lacking, bone grafts and artificial materials such as hydroxyapatite have been used to increase volume.² A novel approach to induce new bone growth may be the application of proteins that modulate wound healing. In particular, bone morphogenetic protein-2 (BMP-2) demonstrates potential for stimulating de novo bone formation.³ While the efficacy of recombinant human BMP-2 (rhBMP-2) has been evaluated in basic science and animal studies, only a few human trials have been completed.^{4–6} The latter employed clinical examination, linear measurements on plain film and computerized tomography (CT) scans, and radiographic photodensitometry.^{6–9} The disadvantage of these evaluation modalities is that they provide a linear measurement versus a volume calculation. The use of CT scans to measure the volume of a region of interest (ROI), for example, of a tumor in the liver (Fiorellini et al, unpublished data; and others^{10,11}), is

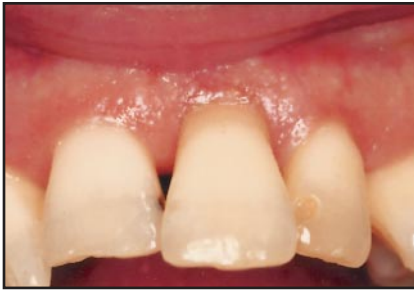

Fig 1a Case treated with rhBMP-2/ACS: preoperative photograph.

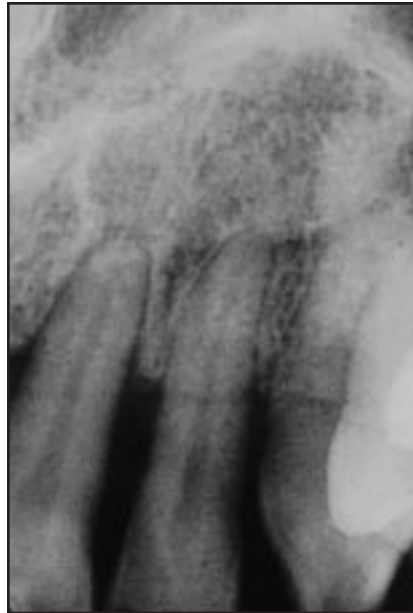

Fig 1b (right) Panoramic radiograph shows periodontal involvement of maxillary left central incisor.

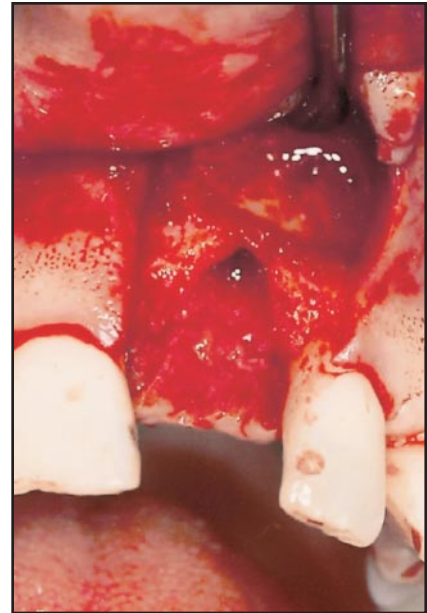


Fig 1c (far right) Intraoperative view shows large buccal wall defect following tooth extraction.

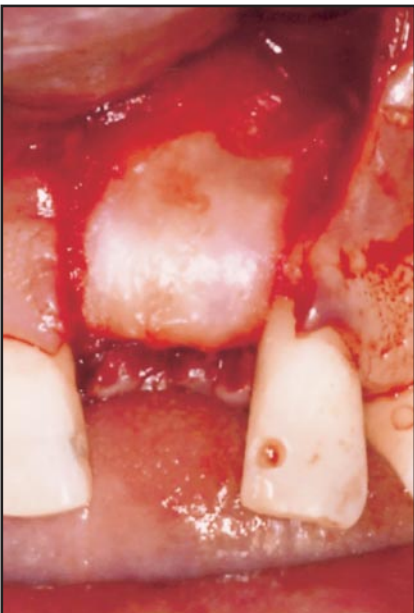
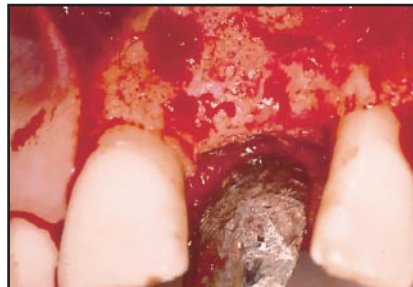
Fig 1d (left) Intraoperative view with rhBMP-2/ACS in place.

Fig 1e (below) Intraoperative view 4 months posttreatment shows restoration of buccal wall.



well-established. Using them to measure the bone volume of extraction sockets poses a unique problem—the absence of at least one boundary, namely the alveolar crest. As bone volume has been considered among the most important factors for successful implant-supported restoration, this article reports the development and use of CT scan methods for the measurement of bone volume changes in extraction sites treated with rhBMP-2.

Method and materials

Data for this study were gathered retrospectively from one center (20 subjects) of an 80-subject multicenter trial.¹² The trial had been

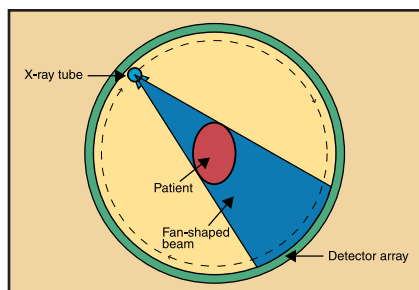
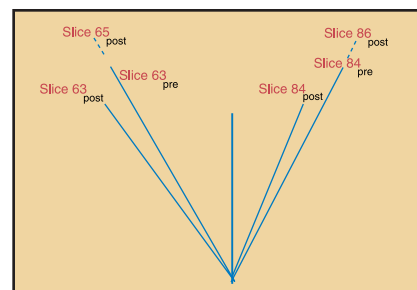


Fig 2 (left) Typical fan-shaped x-ray beam in CT scanner.

Fig 3 (right) Different patient positions during examinations taken at different times, eg, pre- and postoperative, result in slices with the same numbers covering different regions. Consequently, one cannot rely on the slice numbers to determine area or volume of bone in a given region.



approved by the institutional review boards of each of the participating centers. Subjects who required local alveolar ridge augmentation were treated with rhBMP-2/absorbable collagen sponge (ACS) carrier for buccal wall defects following maxillary tooth extraction (Fig 1). Subjects were randomized in a 2:1:1 ratio to receive rhBMP-2/ACS (0.75 or 1.50 mg/mL), placebo (ACS alone), or no treatment. Each patient underwent pre- and postoperative CT scans, which were obtained at baseline (within 4 days following study treatment) and 4 months following study treatment. The protocol included standardization of the CT scans as follows: (1) the hard palate was positioned in a plane perpendicular to the table; (2) the thickness of the slices was fixed; (3) the number of slices was fixed; and (4) the gantry was tilted to 0 degrees.

As the purpose of the present study was to calculate the difference in volume between two identical

ROIs, it had to be certain that the regions selected were in fact as identical as possible. Although the exposure of the CT scans during the original study had been standardized, the images were further standardized so that the CT examiner could consistently define the ROIs. Simplant (version 6.0, Columbia Scientific) was used to analyze the CT scan images and calculate bone volume (cm^3).

Standardizing region of interest

Modern CT scanners use a fan-shaped beam (Fig 2). If, however, during successive CT examinations, a subject is not placed in exactly the same position, specific cross-sectional slice numbers will cover different regions of the anatomy. Referring to Fig 3, assume that one wished to compare the pre- and postoperative bone volume in the region covered by slice numbers

63_{pre} and 84_{pre} ; on the postoperative films, one would have to use slices 65_{post} and 86_{post} . It was therefore not possible to rely on the slice numbers as presented on the CT films.

To compensate for these slight variations, an artificial fan that resulted in a reproducible field of view was created. To establish the mesial and distal boundaries, the original axial slices were viewed, starting from the most coronal slice. The first axial slice where an anatomic landmark, usually a pulp chamber, was clearly represented and for which a corresponding postoperative axial slice could be located was selected. After defining this initial landmark (maxillary right second premolar), a straight line was drawn from the palatal aspect of the pulp chamber to the palatal aspect of the pulp chamber of a second landmark, in this case the maxillary left second premolar (Fig 4). The line was bisected, establishing a midpoint from which a straight line was drawn,

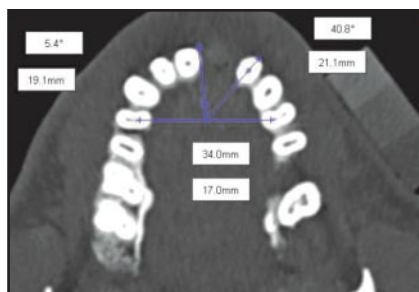


Fig 4 Establishing mesial and distal boundaries of a region. Line drawn from palatal aspect of pulp chamber of maxillary right second premolar to palatal aspect of pulp chamber of left second premolar serves as starting point. Line is bisected; from the bisecting point, a straight line passes through a point on each tooth just mesial and just distal to extraction site.

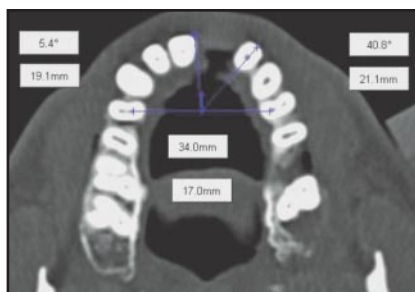


Fig 5 Establishing mesial and distal boundaries on postoperative scans. The series of lines and angles established on the preoperative views are reproduced on the postoperative slices.

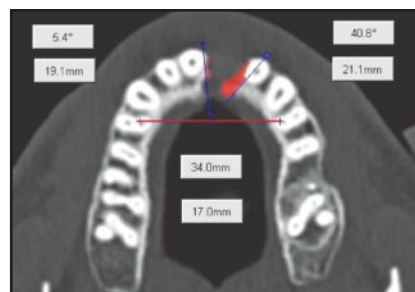


Fig 6 Volume of bone in region of interest is calculated on each axial slice by manual segmentation. Bone outlined by the operator is colored red.

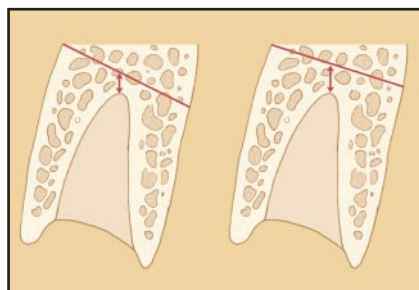


Fig 7 Following segmentation of the axial slices and upon display of the cross-sections, it became apparent that differing amounts of bone had been included beyond the apices on pre- and postoperative slices. This had to be corrected for.

passing through a point on each tooth (eg, pulp chamber, mesial tip of incisal border) just mesial and just distal to the extraction site. In the case illustrated, these were the maxillary right central and the left lateral incisors. Another line was drawn from the midpoint and tangent to the mesial aspect of the maxillary right central incisor. On the axial view of the postoperative CT scan, corresponding landmarks to the first preoperative slices were identified, and similar lines were drawn (Fig 5). These lines and the angles formed by them defined an artificial CT fan that was consistent and delineated the mesiodistal boundaries of the ROI. Using a Simplant tool option, this fan was applied to the more apical axial slices, both pre- and postoperative, until air space was reached and no bone was present.

Once the fan had been applied in the axial slices, axial slices were chosen for analysis. Viewing the axial

slices starting from the most coronal one, a slice in the ROI where bone was first observed was chosen. Each consecutive axial slice was viewed until no bone was visible. Using the Simplant manual segmentation tool, the outline of the bone was traced on the selected axial slices. Tracing the outline of the bone seen in these axial slices ensured that structures from the most coronal aspect of the alveolar defect until slightly beyond the most apical boundary were included. With the aid of the Simplant volume tool, the volume of bone was calculated in each axial slice (Fig 6).

To reduce the possibility of including soft tissue rather than bone volume, a thresholding technique was applied. The software was directed to include only those pixels that had values greater than 150 Hounsfield units, the number typically used in clinical practice as the threshold for bone. After tracing all

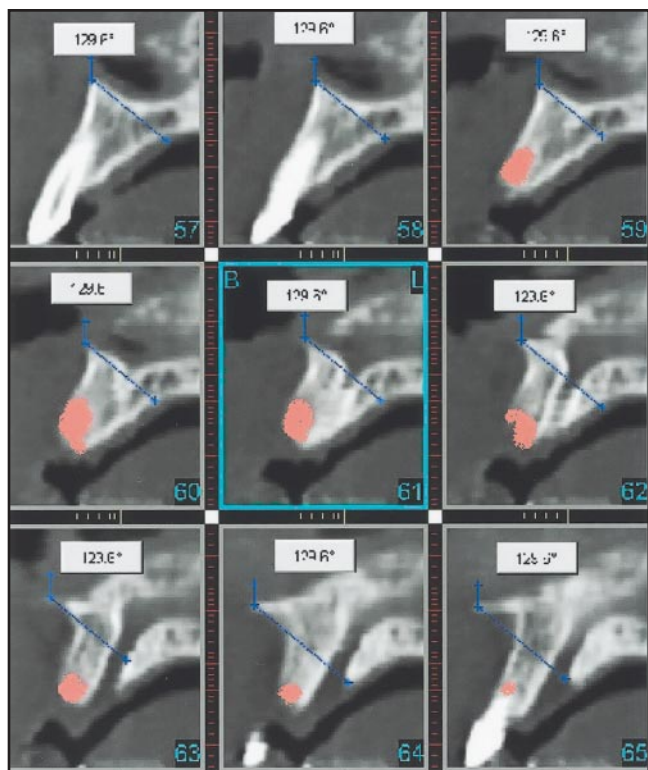
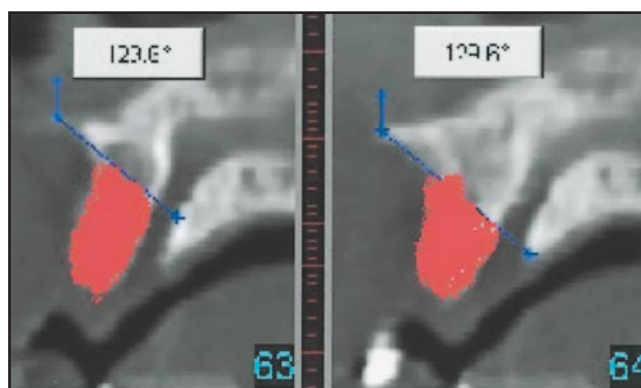


Fig 8a (left) Defining superior limit of region of interest. Typically, anterior nasal spine and palatal margin of incisive canal were selected as the boundary. This is well-illustrated in slice 62.

Fig 8b (below) Slices following complete manual segmentation and definition of superior border.



the axial slices and applying the threshold, the total amount of bone volume in the ROI was obtained.

After the mesial and distal borders had been defined and the bone on the selected axial slices traced, the corresponding cross-sectional slices were displayed. On the latter, it became evident that bone above the apex of the tooth, and thus outside the ROI, had been included. Furthermore, there was not a consistent superior (apical) border between the pre- and postoperative slices, meaning that the ROI had been defined differently (Fig 7). Using the cross-sectional images, the superior margin was standardized. Beginning with the

preoperative slices, two consistently reproducible bony landmarks were chosen on one particular slice. The landmarks had to be identifiable in the corresponding postoperative cross-sectional images. Typically, the anterior nasal spine and palatal margin of the incisive canal were selected. A line was drawn from the spine downward and palatally toward the incisive canal. The line so drawn and the angle so obtained defined the upper limit of the ROI (Fig 8).

Using the same landmarks, a similar line was drawn in each postoperative cross-sectional slice. The line was initially drawn on the postoperative slice that corresponded

most closely with the first preoperative cross-sectional slice. Because of slightly different positions of the patient during the scanning procedures, there was a difference in angulation between the pre- and postoperative lines. It was arbitrarily decided that if the difference was greater than 5 degrees, the patient would be excluded from the study. No case exceeded this limit. The angle obtained in the selected postoperative view was applied to all postoperative cross-sectional slices. The bone above the newly created superior margin was removed on the cross-sectional slices, and the Simplant software recalculated the volume of bone.

Table 1 Intraoperator error (mL)*			
Patient	Measurement 1	Measurement 2	Measurement 3
RL	0.09	0.09	0.08
EMC	0.07	0.07	0.08
EL	0.12	0.14	0.13

* $P > .400$.

Table 2 Comparison of indirect and direct measurements (mL) to validate the indirect method*			
Patient	Indirect measurement	Direct measurement	Absolute difference
EJH	0.11	0.12	0.01
MM	0.13	0.12	0.01
MN	0.29	0.31	0.02
LA	0.08	0.08	0.00
RHH	0.06	0.07	0.01
Mean	0.134	0.140	
Standard deviation	0.090	0.097	

* $P > .125$.

Validation of indirect CT volume measurements

To establish whether the methodology employed was reasonably accurate, a direct measurement of new bone volume that formed within a socket was performed. Five cases in which it appeared that new bone was readily identifiable were selected. The operator manually segmented the new bone in each postoperative CT image. The Simplant software calculated this bone volume. The results for the five cases were compared with the volume measurements using the indirect technique.

Statistical analysis

Using the Statistical Analysis System (SAS Institute), descriptive statistics were calculated for the change in bone volume, with the patient as the unit of measure. Treatment groups were compared using the Kruskal-Wallis and Wilcoxon rank-sum tests. Direct and indirect volume measurements were compared using the Wilcoxon signed ranks test. To evaluate intraexaminer error, the examiner measured preoperative images from three randomly selected study cases. The examiner repeated this procedure for all images three times, with a new randomized order. Intraoperator error

was evaluated using the Kruskal-Wallis test.

Results

With the Simplant program, a total of 40 CT studies (20 pre- and 20 postoperative) were evaluated. Patients in the radiographic study consisted of 12 men and 8 women, with a mean age of 53.2 years.

The mean new bone volumes for the treatment groups were 0.104 cm³ (standard deviation [SD] 0.063) for the untreated group, 0.084 cm³ (SD 0.044) for the group treated with rhBMP-2 at a concentration of 0.00 mg/mL, 0.106 cm³ (SD 0.033) for the group treated with rhBMP-2 at a concentration of 0.75 mg/mL, and 0.192 cm³ (SD 0.064) for the group treated with rhBMP-2 at a concentration of 1.50 mg/mL. There was a statistically significant difference in bone formation between subjects treated with rhBMP-2 at a concentration of 1.50 mg/mL compared with each of the other groups ($P < .050$). There was no statistically significant difference in bone volume between any of the other groups. None of the groups showed a loss in bone volume.

The means of the three measurements performed to evaluate intraoperator error were 0.086 cm³ (SD 0.006) for the first patient, 0.073 cm³ (SD 0.006) for the second patient, and 0.097 cm³ (SD 0.029) for the third patient (Table 1). There were no statistically significant differences between any of the three means. The mean for the indirect

measurement method was 0.134 cm³ and 0.140 cm³ for the direct method (Table 2). The mean absolute difference between the measurements was 0.010 cm³ (SD 0.007). There was no statistically significant difference between the two techniques.

Discussion

Short of reentry into the site, radiography offers the best way to determine the efficacy of ridge augmentation materials. The utility of radiography depends on the nature of the examination. For example, periapical films by themselves provide limited information and are thus frequently combined with subtraction radiography.¹³ Advanced imaging modalities such as CT, especially three-dimensional CT, when combined with subtraction radiography, provide the best information. Three-dimensional subtraction radiography, however, is expensive and not readily available everywhere, or access may be restricted.

CT measurements of the total volume of large organs are well-described. Heymsfield et al¹¹ established that the area of an organ slice can be calculated using a standard grid printed on the film. Because the width between slices is known, the volume of an organ slice can be calculated as area multiplied by width. Others¹² used CT on phantoms, dog kidneys *in vivo*, and human spleens before splenectomy to calculate cross-sectional areas. Volumes were then determined with each of four

mathematic integration techniques. Volume estimations were compared to volumes determined by water displacement. Moss et al¹⁰ measured the volume of canine livers and kidneys by CT. They showed that organ volume determination by CT is a rapid and simple procedure accurate to $\pm 5\%$ of the organ volume as measured by the water displacement technique. Individual measurements are reproducible to within $\pm 3\%$. Using spiral CT on phantoms, Tiitola et al¹⁴ estimated the volume of tumors. Those authors document that computer-based methods to measure volume are reliable and especially recommend their use for film readers with limited radiologic experience.

Techniques to measure bone volume in the jaws have not been well-described. The aim of the present study was to use CT scans typically used in implant planning to measure the change in bone volume in buccal wall defects in the maxilla following tooth extraction and treatment with rhBMP-2. As we wished to measure the change in size of alveolar defects pre- and postoperative, ideally we would have liked to measure the size of the defects themselves. However, the lack of one or more borders created certain difficulties. One way of dealing with the missing crestal cortex is to define the defect by simply connecting the buccal and palatal crestal cortices, but this can make the interpretation of the data extremely difficult and of little or no use, as illustrated in Fig 9.

We overcame our inability to define the defect directly by ignoring

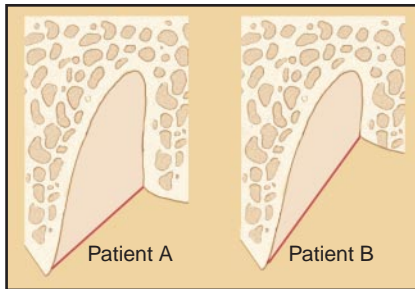


Fig 9 Missing crestal cortex poses a unique problem when attempting to measure volume of a defined region. If, eg, one compares the alveolar defect in patient A with that in patient B by simply connecting buccal and palatal crestal cortices, defect in patient A would measure larger than that in patient B, although patient A will clearly have more bone if both defects fill following treatment.

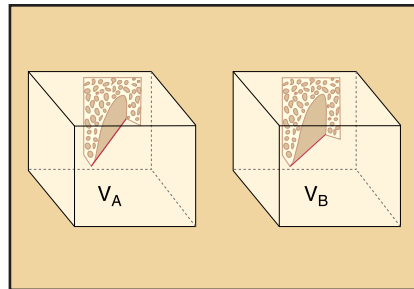


Fig 10 As it is not possible to directly measure the size of a defect missing a border, change in bone volume within the socket is calculated by selecting a region larger than, but including, the extraction site. Same region of interest is selected pre- (V_A) and postoperative (V_B). Assuming that the only change in bone volume within the region selected occurs within the extraction socket, absolute change in bone volume can be measured irrespective of defect shape.

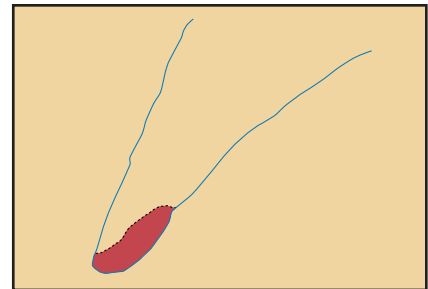


Fig 11 Cross-sectional image through anterior maxilla illustrates why indirect method was used to measure bone volume; solid blue line = preoperative ridge; dotted black line = postoperative ridge; red area = bone that was lost. Had the direct method been used, volume of hatched region would have had to be measured on a postoperative image that did not show the preoperative ridge.

its dimensions and measuring the absolute amount of bone change in an ROI that was larger than, but included, the extraction site. The same region was selected on both the pre- and postoperative CT scans. We assumed that the only change in bone volume that would occur within the region selected was in the area of the extraction socket, making it possible to measure the absolute change in bone volume following treatment (Fig 10), while still meeting our primary objective, determining the efficacy of BMP.

Comparison of the direct and indirect measurement techniques

showed the latter method to be reliable. As measuring the volume of new bone directly is faster than the indirect method, one might assume that it ought to be the method of choice. We did not use it because, at the outset of the study, we did not know whether some sites would lose bone. If that had happened, we would have had to measure a negative—bone that had been lost and could not be seen on the postoperative images when viewed in isolation from the preoperative images (Fig 11). In that case, we would have had to resort to the indirect method.

While the method described here is not likely to be used by the practicing clinician, it is useful in the clinical research setting to evaluate the efficacy of bone augmentation procedures. The method provides a means to measure small changes in bone volume in areas where it may be difficult or impossible to define the boundaries of the area in question. Such difficulties are likely to be encountered, for example, in cases in which extraction sockets are treated immediately following extraction, thus destroying the outline of the natural socket.

Conclusion

The 1.5 mg/mL rhBMP-2 dose was able to induce bone growth in buccal wall defects in the maxilla following tooth extraction. Although the methodologies used were adequate to detect differences in bone volume between treatment groups, the following additional recommendations can be incorporated into future studies. The use of the same CT equipment during all examinations, calibrated CT technicians, and laser light locators to ensure consistent patient positioning during the pre- and postoperative CT examinations would greatly standardize the procedure. Potential patient movement could be minimized through multidetector CT machines that can perform a study rapidly. A stent that can maintain a fixed and consistent position of the jaw, especially the mobile mandible, would be helpful. The establishment of a gold standard against which to measure the radiographic results and efficacy of ridge augmentation is highly desirable. Such a standard would involve direct pre- and postoperative measurement of the defect by filling it with an appropriate material and determining the volume from the amount of material used.

Acknowledgments

This study was supported in part by grants from Wyeth/Genetics Institute and Harvard School of Dental Medicine, Division of Periodontology.

References

- Masuda T, Yliheikkilä PK, Felton DA, Cooper LF. Generalizations regarding the process and phenomenon of osseointegration. Part I. In vivo studies. *Int J Oral Maxillofac Implants* 1998;13:17–29.
- LeGeros RZ, Craig RG. Strategies to affect bone remodeling: Osteointegration. *J Bone Miner Res* 1993;8(suppl 2): S583–S596.
- Wozney JM. Bone morphogenetic proteins. *Prog Growth Factor Res* 1989;1: 267–280.
- Boyne PJ, Marx RE, Nevins M, et al. A feasibility study evaluating rhBMP-2/ absorbable collagen sponge for maxillary sinus floor augmentation. *Int J Periodontics Restorative Dent* 1997;17: 11–25.
- Cochran DL, Schenk R, Buser D, Wozney JM, Jones AA. Recombinant human bone morphogenetic protein-2 stimulation of bone formation around endosseous dental implants. *J Periodontol* 1999;70: 139–150.
- Howell TH, Fiorellini J, Jones A, et al. A feasibility study evaluating rhBMP-2/absorbable collagen sponge device for local alveolar ridge preservation or augmentation. *Int J Periodontics Restorative Dent* 1997;17:124–139.
- Toriumi DM, Kotler HS, Luxenberg DP, Holtrop ME, Wang EA. Mandibular reconstruction with a recombinant bone-inducing factor. Functional, histologic and biomechanical evaluation. *Arch Otolaryngol Head Neck Surg* 1991;117:1101–1112.
- Toriumi DM, O'Grady K, Horlbeck DM, Desai D, Turek TJ, Wozney J. Mandibular reconstruction using bone morphogenetic protein 2: Long-term follow-up in a canine model. *Laryngoscope* 1999;109: 1481–1489.
- Zellin G, Lindé A. Bone neogenesis in domes made of expanded polytetrafluoroethylene: Efficacy of rhBMP-2 to enhance the amount of achievable bone in rats. *Plast Reconstr Surg* 1999;103: 1229–1237.
- Moss AA, Cann CE, Friedman MA, Marcus FS, Resser KJ, Berninger W. Volumetric CT analysis of hepatic tumors. *J Comput Assist Tomogr* 1981;5: 714–718.
- Heymfield SB, Fulenwider T, Nordlinger B, Barlow R, Sones P, Kutner M. Accurate measurement of liver, kidney, and spleen volume and mass by computerized axial tomography. *Ann Intern Med* 1979;90: 185–187.
- Breiman RS, Beck JW, Korobkin M, et al. Volume determinations using computed tomography. *AJR Am J Roentgenol* 1982; 138:329–333.
- Webber RL, Ruttimann UK, Grondahl HG. X-ray image subtraction as a basis for assessment of periodontal changes. *J Periodontol Res* 1982;17:509–511.
- Tiitola M, Kivisaari L, Tervahartiala P, et al. Estimation or quantification of tumour volume? CT study on irregular phantoms. *Acta Radiol* 2001;42:101–105.